



Pigment Dispersion Syndrome after Implantation of Evo-Implantable Collamer Lens (ICL) in a Patient with Concave Iris Configuration

Lucy Yuan, MD

James Bailey, MD

Madigan Army Medical Center

Disclaimer: The authors of this poster have no financial disclosures. The views expressed in this presentation are of the speakers and not representative of the United States Military, Defense Health Agency, or the United States Government.

Introduction

- Pigment dispersion syndrome is an uncommon but known complication of ICL implantation thought to occur even less commonly in central hole ICL lenses and more commonly in the setting of high vaults^{4,7}
- A clinical trial done by the FDA in 2022 showed that EVO-ICL lenses eliminated the need for preoperative peripheral iridotomies, and notably of the 629 eyes that were included in the study, none of them developed pigment dispersion or secondary glaucoma⁶

Purpose

To report a case of pigment dispersion syndrome secondary to the implantation of implantable collamer lens (ICL) with central hole (EVO Visian ICL, STAAR Surgical) in a patient with known concave iris configuration.

Case Presentation

27 y/o Myopic Male presents for refractive surgery evaluation

- No past ocular history
- Not a candidate for laser refractive surgery due to: Flat post operative Ks

Manifest Refraction:

OD -5.00 -1.25 x014 20/20

OS -4.25 -1.00 x180 20/20

Anterior segment OCT:

OD: ACD 3.09mm, Angle 48 deg T, 48 deg N, lens rise 93, ata 12.59

OS: ACD 3.19mm, Angle 47 deg T, 53 deg N, lens rise 45, ata 12.18

Gonio:

OD: Grade IV, trace pigment, concave iris

OS: Grade IV, trace pigment, concave iris

Patient underwent uncomplicated ICL surgery OU

POD1	OD	OS
VA	20/25-2 PH 20/20 -1	20/20-2
IOP	17	16
Vaults	500 uM	500 uM

POW1	OD	OS
VA	20/20-1	20/20
IOP	20	18
Vaults	500 uM	500 uM

Slit Lamp Exam	
Cornea	Wounds sealed OU
AC	Trace cell OU
Iris	Round, flat OU
Lens	ICL well-centered OU

Post-operative Month 1

POM1	OD	OS
VA	20/20	20/20
IOP	12	13
Vaults	500 uM	500 uM

- Vault and ICL position stable
- No inflammation
- New mid-peripheral TIDs
- New pigment on ICL OU
- Continue to monitor
- Follow up at POM3

Slit Lamp Exam

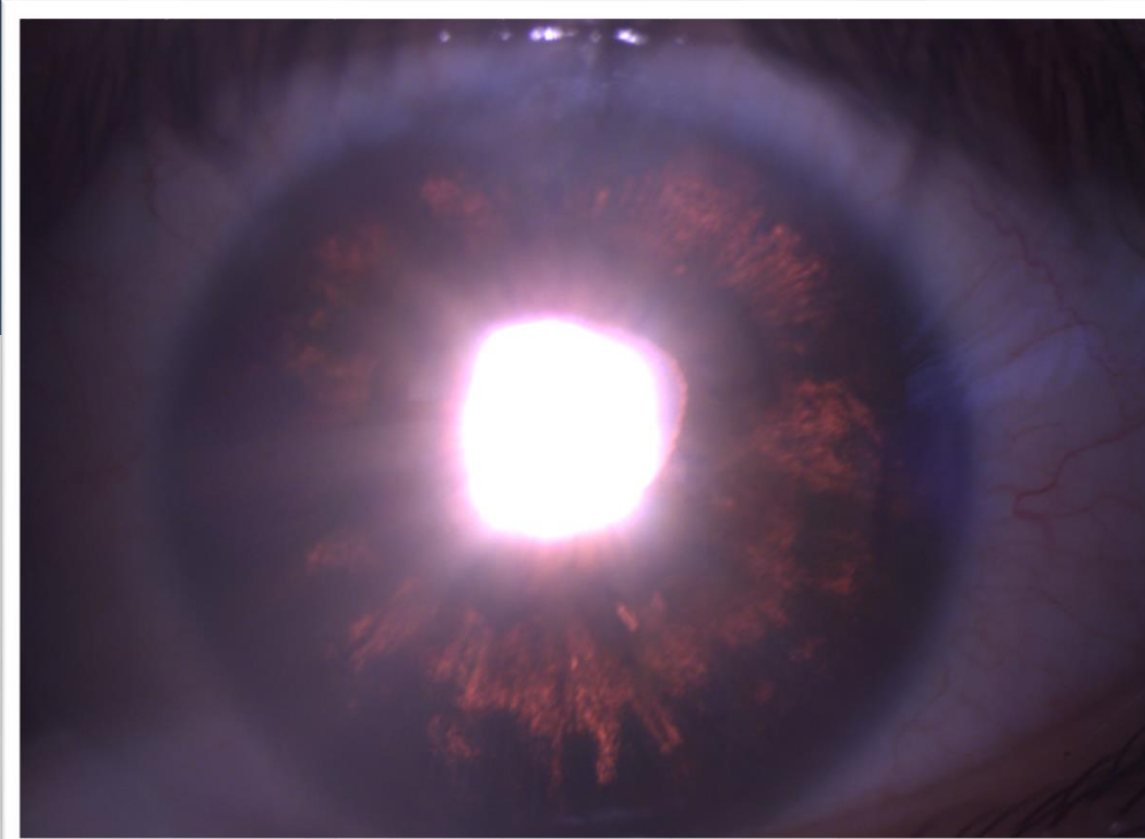
Cornea	Clear OU
AC	Deep and quiet OU
Iris	Round, flat OU, 270 mid-peripheral TID OU
Lens	ICL well-centered OU, pigment on ICL

Post-operative Month 3

POM3	OD	OS
VA	20/20	20/20-1
IOP	17	18
Vaults	300 uM	300 uM

Slit Lamp Exam

Cornea	Clear OU
AC	OD: 1 pigment cell per HPF OS: 1-3 pigment cell per HPF
Iris	270 mid-peripheral TID OS > OD
Lens	ICL well-centered OU, pigment on ICL

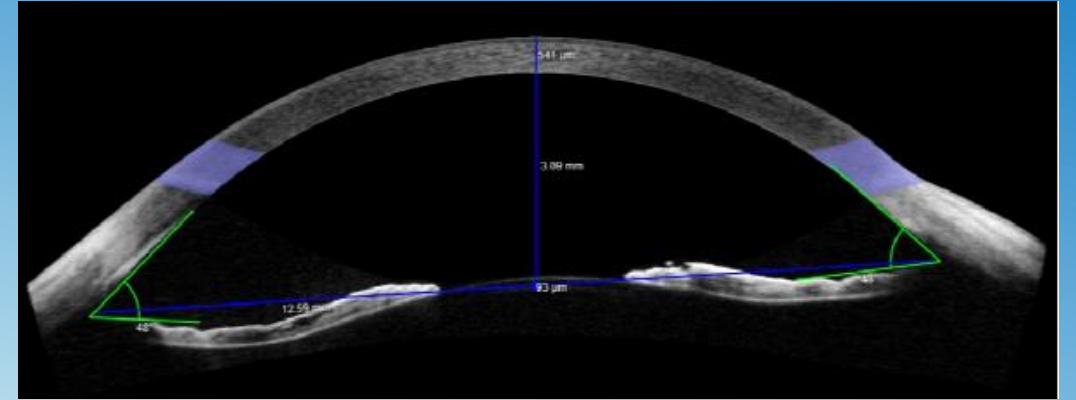
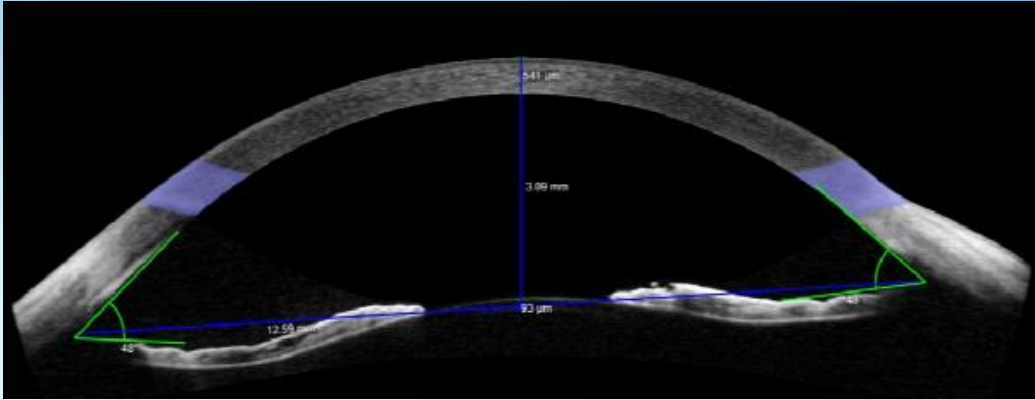


- Good vaults, but worsening iris atrophy and new AC pigment OU
- IOP wnl, no RNFL thinning
- Discussion of R/B/A of conservative monitoring versus ICL explantation

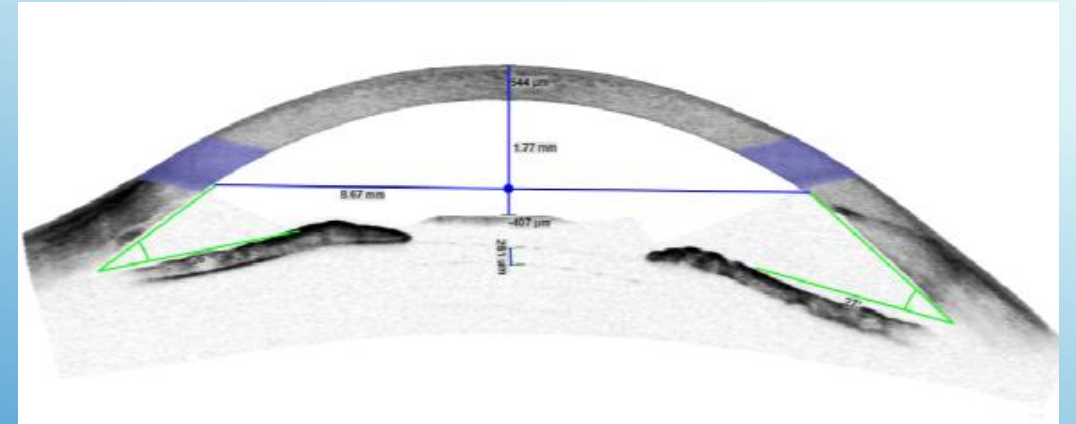
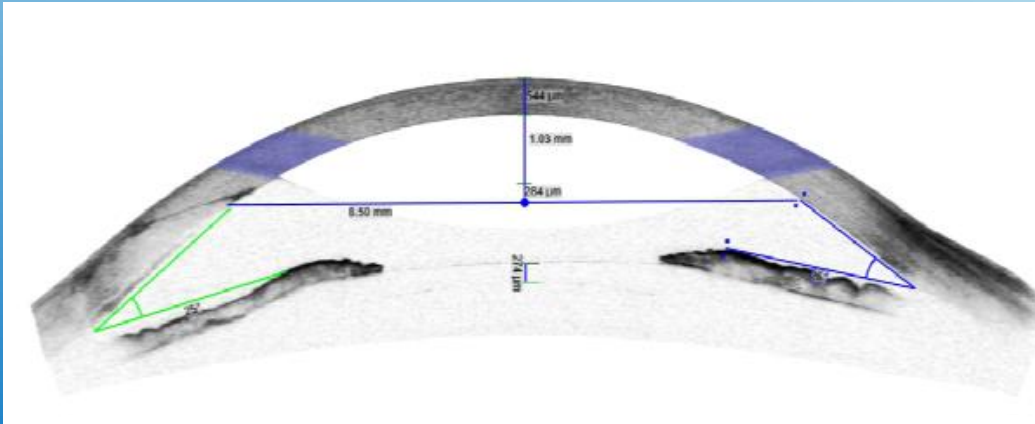
OD

Pre-operative Anterior Segment OCT

OS



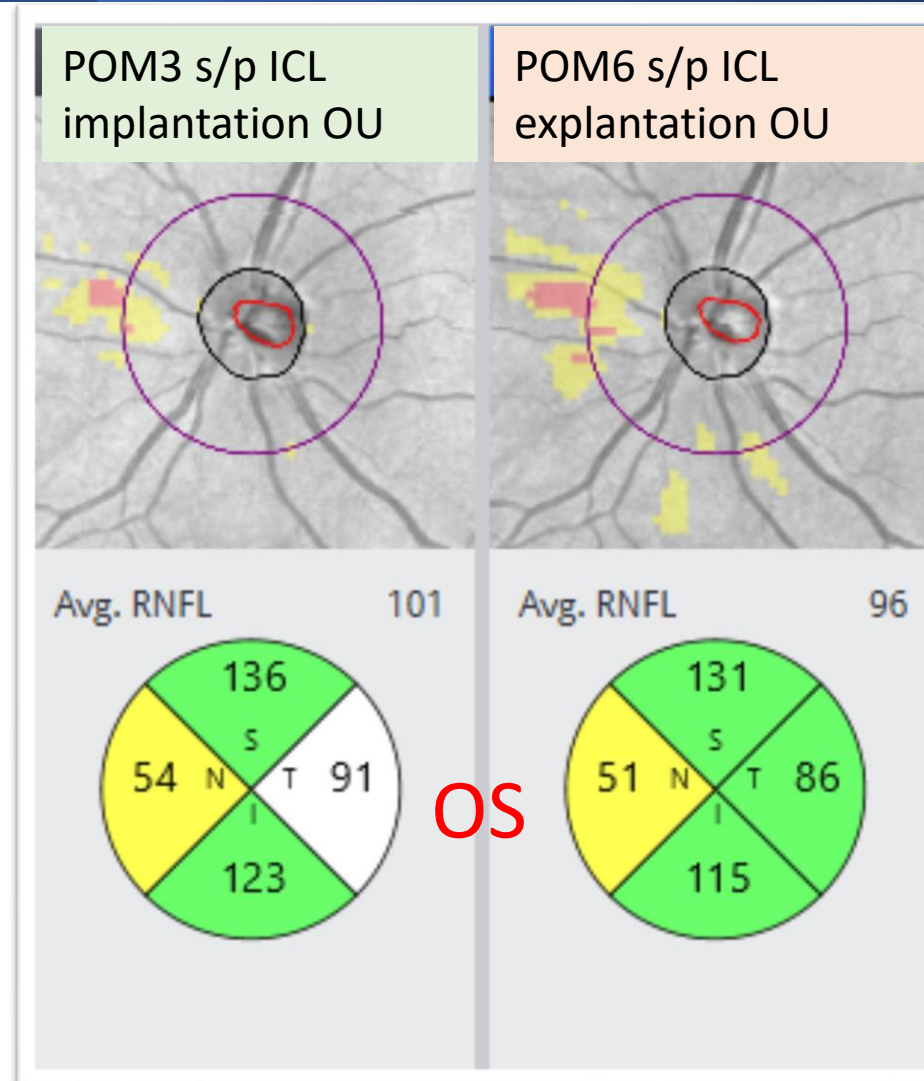
Post-operative Month 3 Anterior Segment OCT



Narrow anterior chamber angles noted on AS-OCT after ICLs placed
ICL was verified to be correct size based on pre-operative AS-OCT

Post-operative Month 6 s/p ICL Explant

- ICL Explantation surgery uncomplicated
- Vision stable with updated mRx (20/20 OU)
- IOP controlled though slightly elevated
 - (OD 23, OS 22)
- Cornea clear OU without edema
- RNFL with mild progression OS, and stable OD
- Recommendation for SLT, but patient moving, thus started on latanoprost QHS OU



Discussion

- Several cases have reported transient increases in pigment dispersion after ICL implantation that resolve with conservative management.^{1,2}
- It has also been suggested that ICL implantation does not increase angle pigmentation compared to traditional peripheral iridotomies in lenses without central holes^{3,5}
- Other studies have suggested that EVO-ICL implantation is safe in patients with concave iris morphology and may actually improve iris morphology.⁸
- In this case, the patient had concave iris morphology with uncomplicated ICL implantation OU who went on to develop pigment dispersion syndrome despite excellent vaults

Conclusion

- Some studies have suggested that ICL surgery may be safe or even beneficial in patients with concave irises
- This case report suggests that ICL implantation should be avoided in patients with concave iris configuration even in those without preoperative signs of pigment dispersion syndrome

References

1. Brandt JD, Mockovak ME, Chayet A. Pigmentary dispersion syndrome induced by a posterior chamber phakic refractive lens. *Am J Ophthalmol.* 2001 Feb;131(2):260-3. doi: 10.1016/s0002-9394(00)00606-1. PMID: 11228308.
2. Chaudhary, Sanjay MS; Mehra, Hema MS; Mittal, Shanu Kumar MS; Pandey, Alka MS. Early pigment dispersion and raised intraocular pressure after uneventful central-hole implantable collamer lens surgery. *JCRS Online Case Reports* 11(3):p e00096-4, July 2023. | DOI: 10.1097/j.jcro.0000000000000096
3. Chun YS, Park IK, Lee HI, Lee JH, Kim JC. Iris and trabecular meshwork pigment changes after posterior chamber phakic intraocular lens implantation. *J Cataract Refract Surg.* 2006 Sep;32(9):1452-8. doi: 10.1016/j.jcrs.2006.04.023. PMID: 16931255.
4. Huang D, Schallhorn SC, Sugar A, Farjo AA, Majmudar PA, Trattler WB, Tanzer DJ. Phakic intraocular lens implantation for the correction of myopia: a report by the American Academy of Ophthalmology. *Ophthalmology.* 2009 Nov;116(11):2244-58. doi: 10.1016/j.ophtha.2009.08.018. PMID: 19883852.
5. Martínez-Plaza E, López-de la Rosa A, Ossa-Calderon C, Blázquez-Arauzo F, López-Miguel A, Maldonado MJ. Assessment of the iridocorneal angle pigmentation and structures after the implantation of EVO+ Visian Implantable Collamer Lens. *Int Ophthalmol.* 2023 Dec;43(12):4711-4718. doi: 10.1007/s10792-023-02871-3. Epub 2023 Sep 11. PMID: 37697080.
6. Packer M. Evaluation of the EVO/EVO+ Sphere and Toric Visian ICL: Six Month Results from the United States Food and Drug Administration Clinical Trial. *Clin Ophthalmol.* 2022 May 21;16:1541-1553. doi: 10.2147/OPTH.S369467. PMID: 35645557; PMCID: PMC9132105.
7. Zhang H, Gong R, Zhang X, Deng Y. Analysis of perioperative problems related to intraocular Implantable Collamer Lens (ICL) implantation. *Int Ophthalmol.* 2022 Nov;42(11):3625-3641. doi: 10.1007/s10792-022-02355-w. Epub 2022 Jun 22. PMID: 35731355; PMCID: PMC9587946.
8. Zhang Z, Niu L, Liu T, Shen Y, Shang J, Zhao J, Wei R, Zhou X, Yao P. Primary observations of EVO ICL implantation for high myopia with concave iris. *Eye Vis (Lond).* 2023 Apr 2;10(1):18. doi: 10.1186/s40662-023-00335-4. PMID: 37005642; PMCID: PMC10068169.